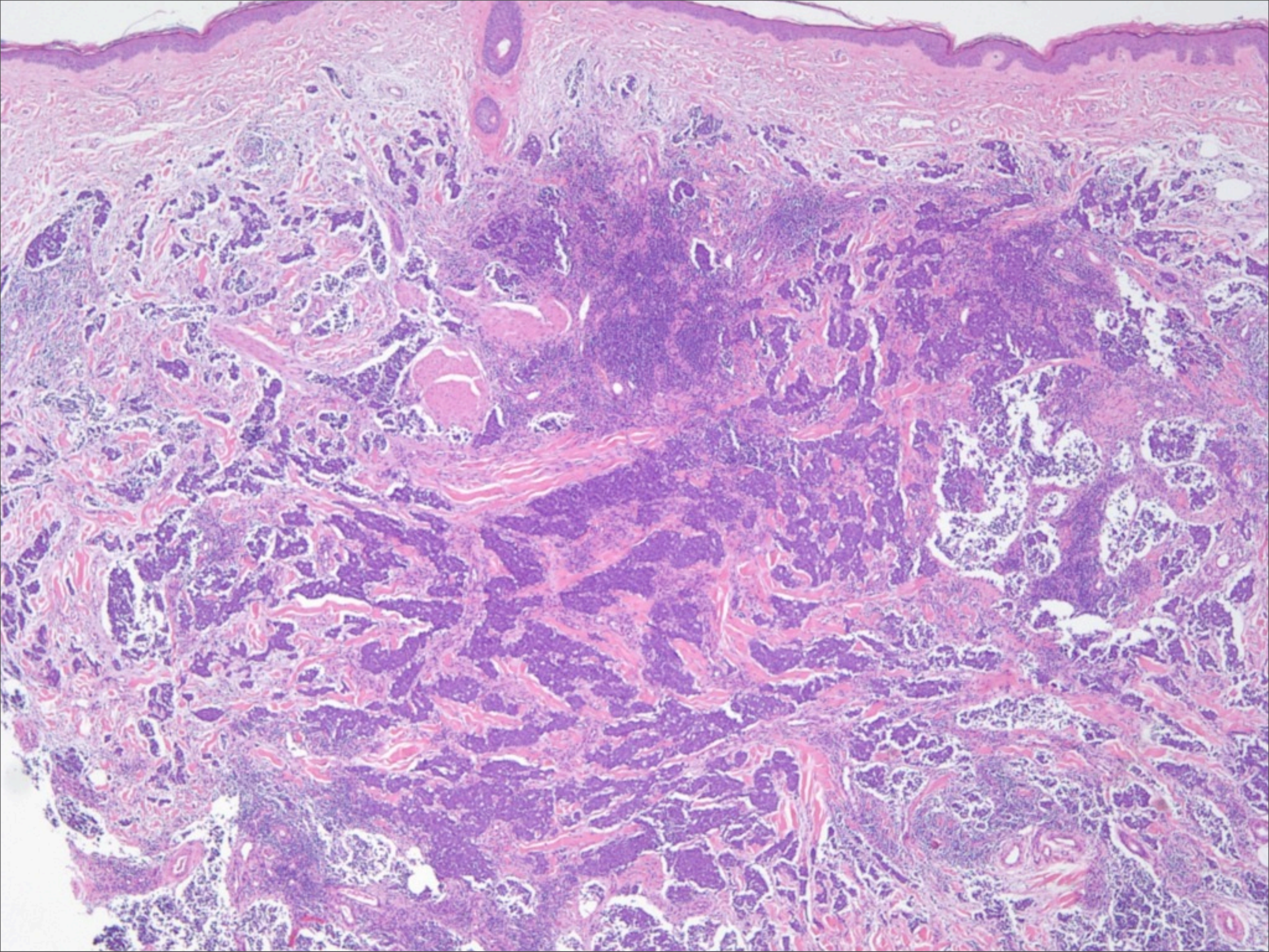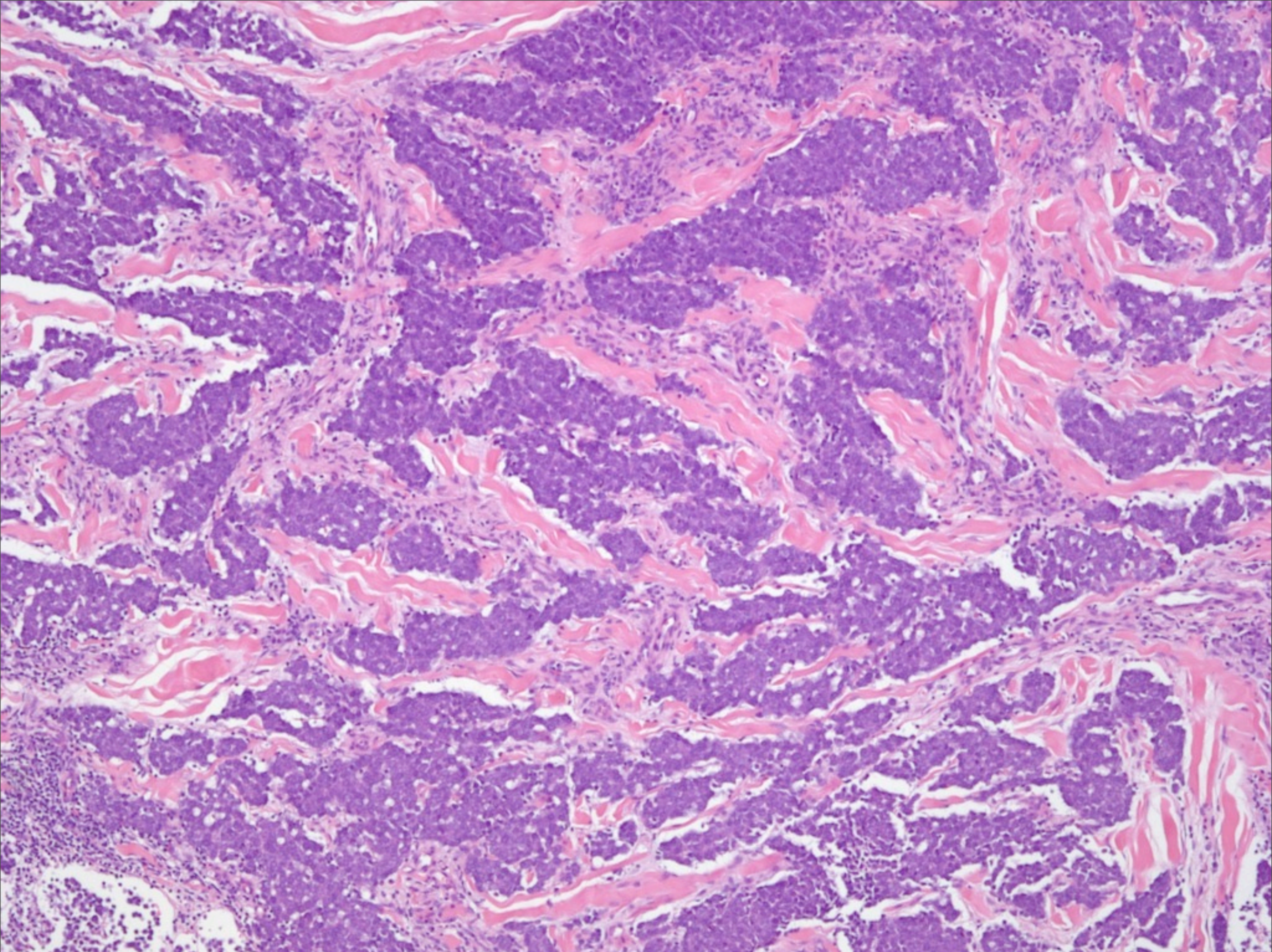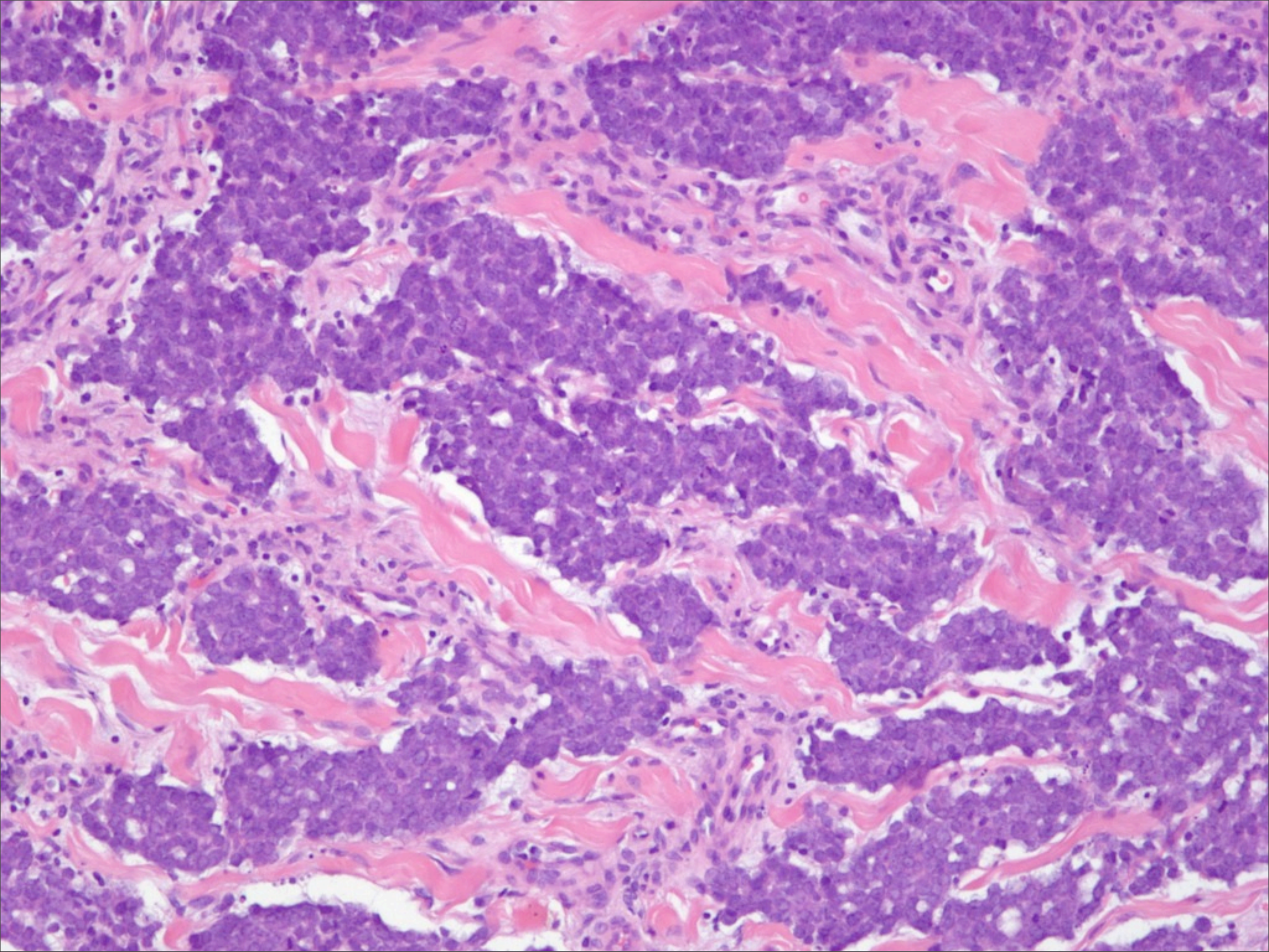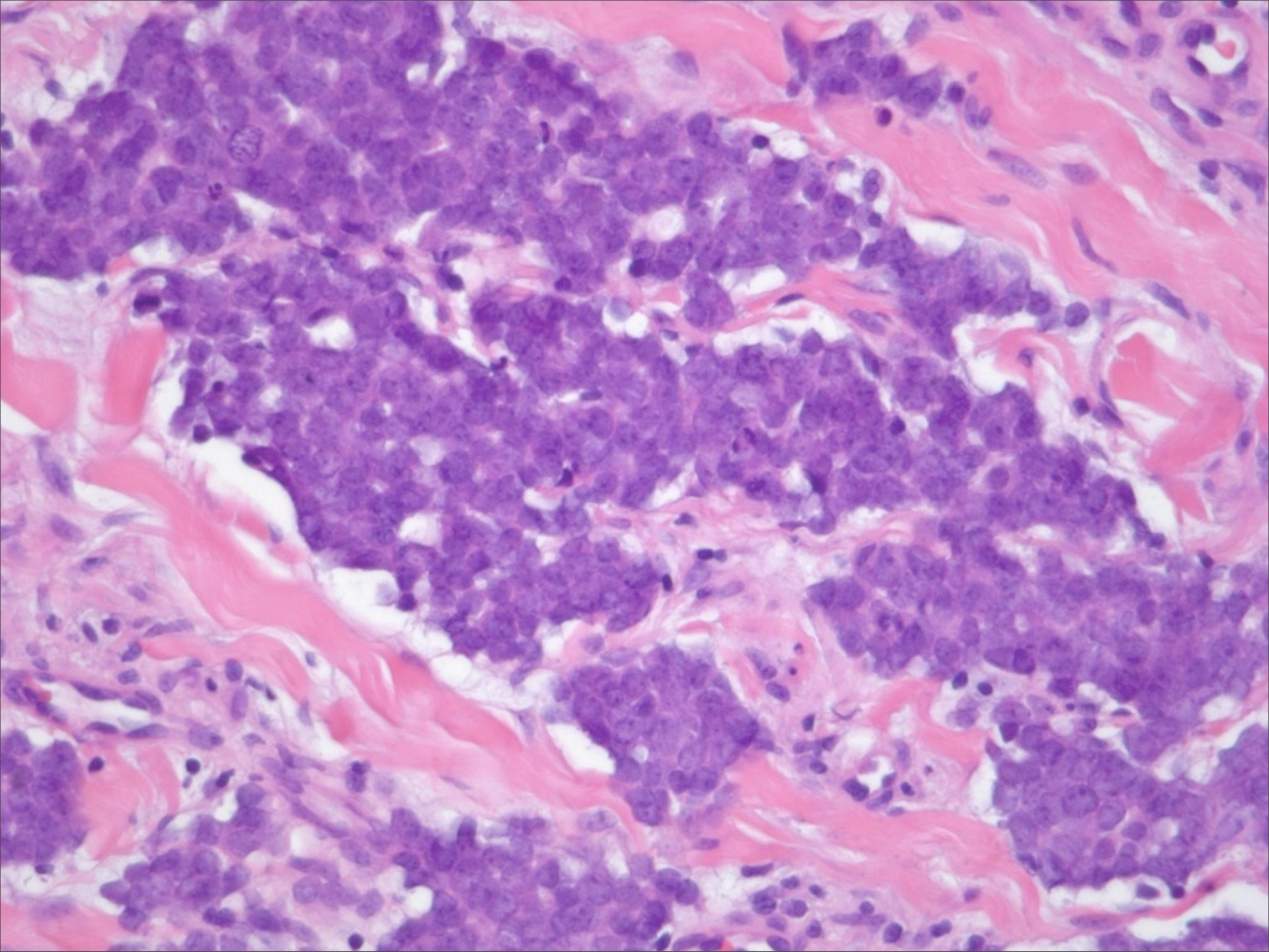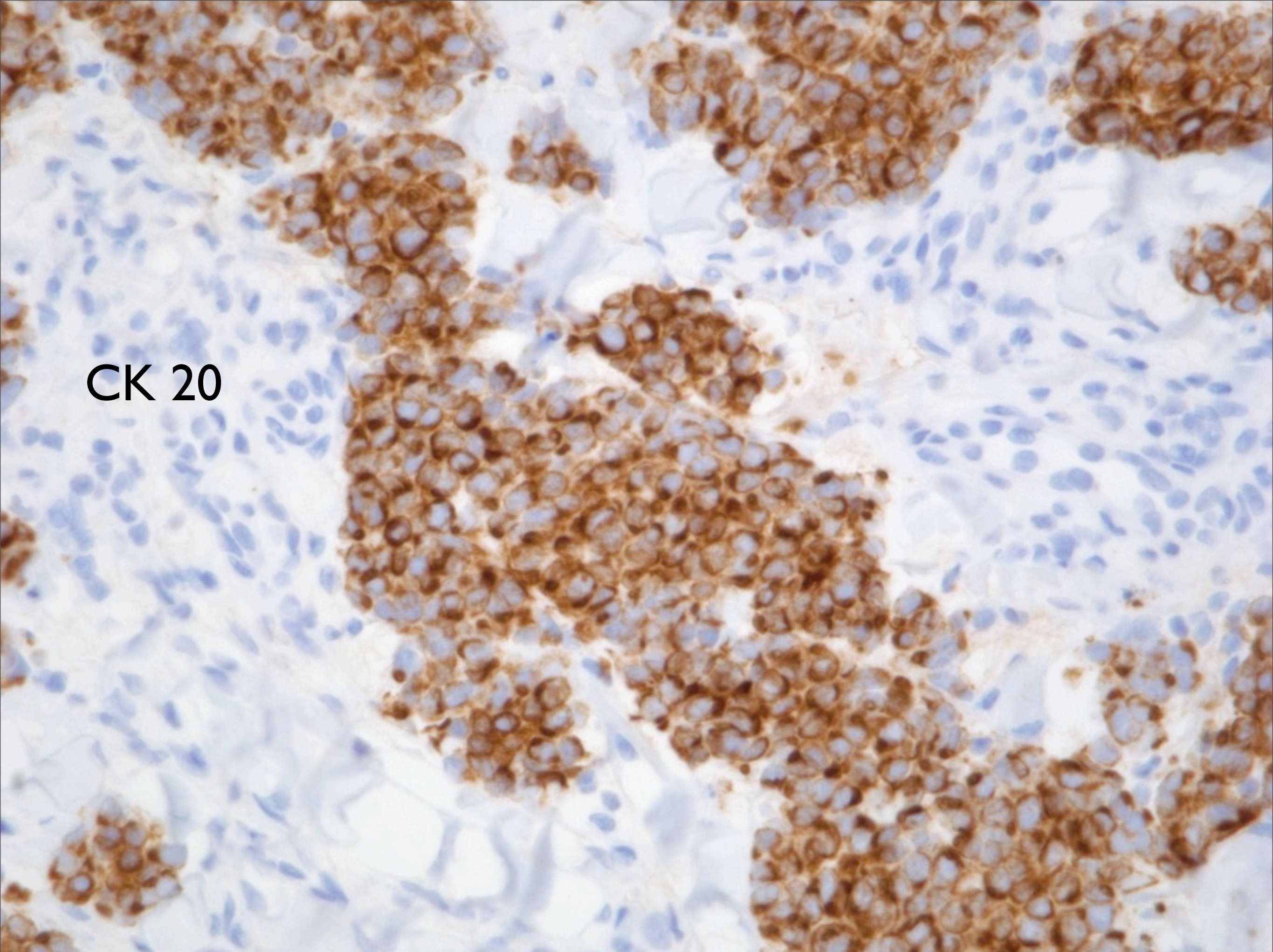
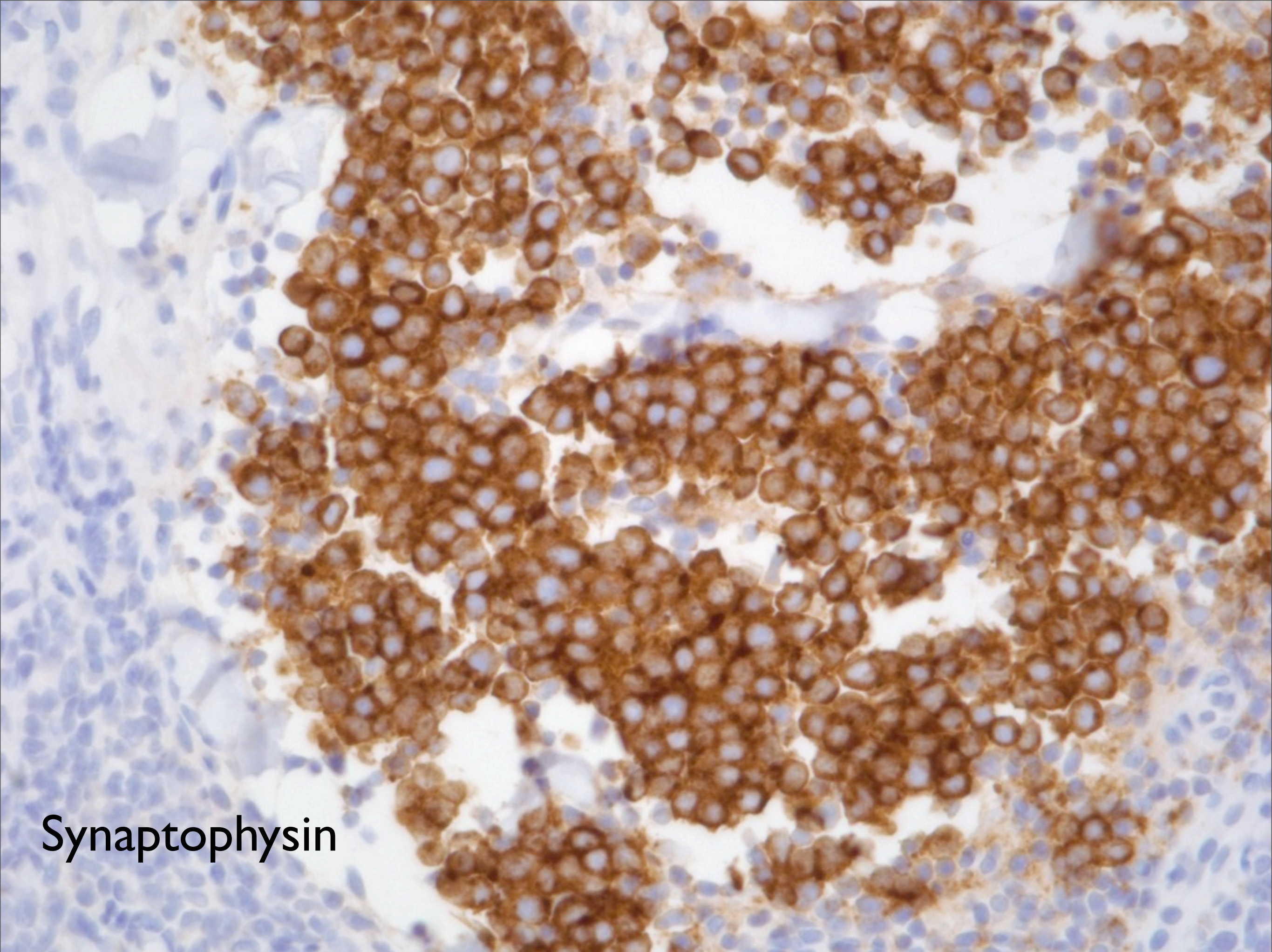




CK 20





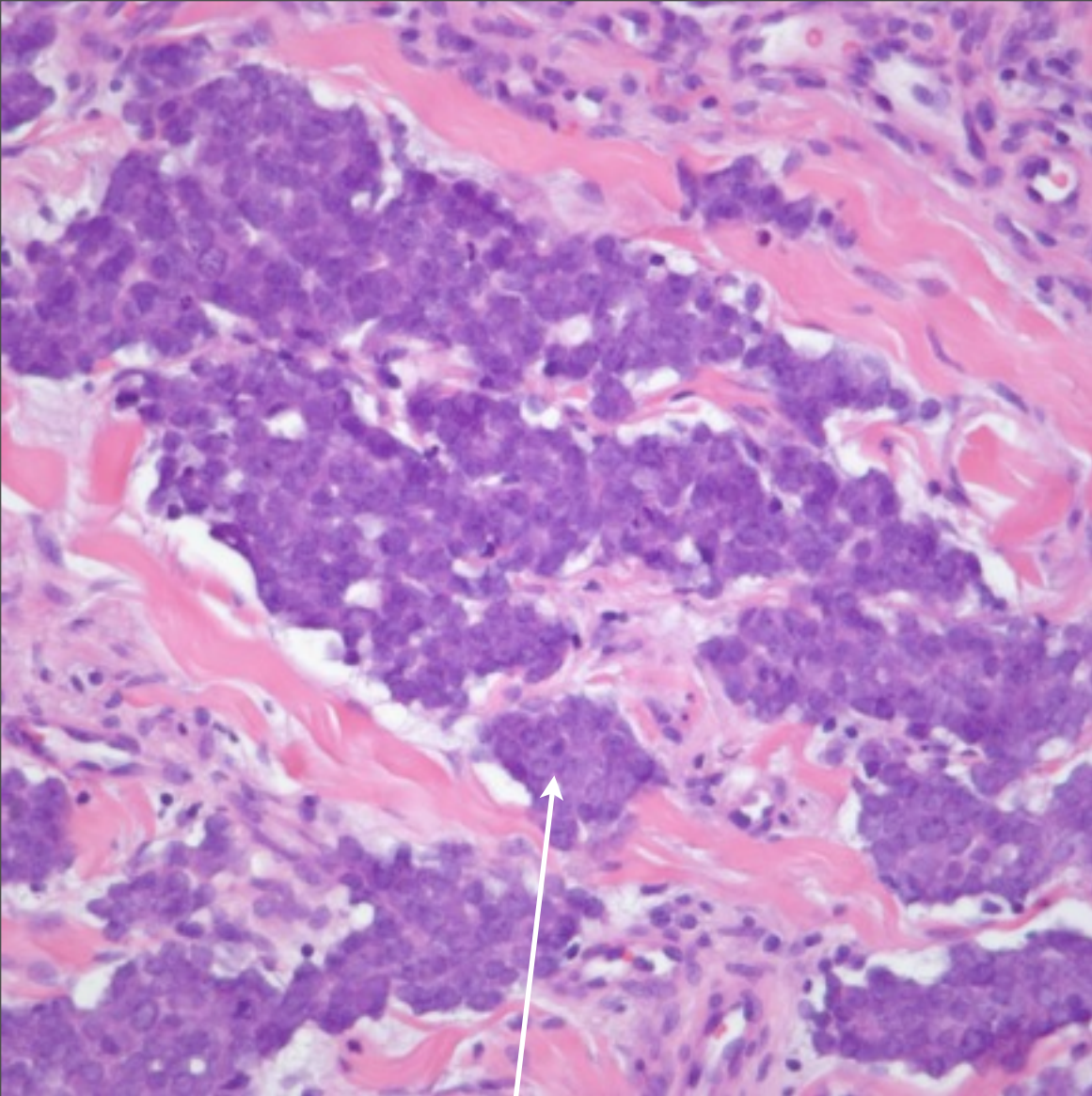


Synaptophysin

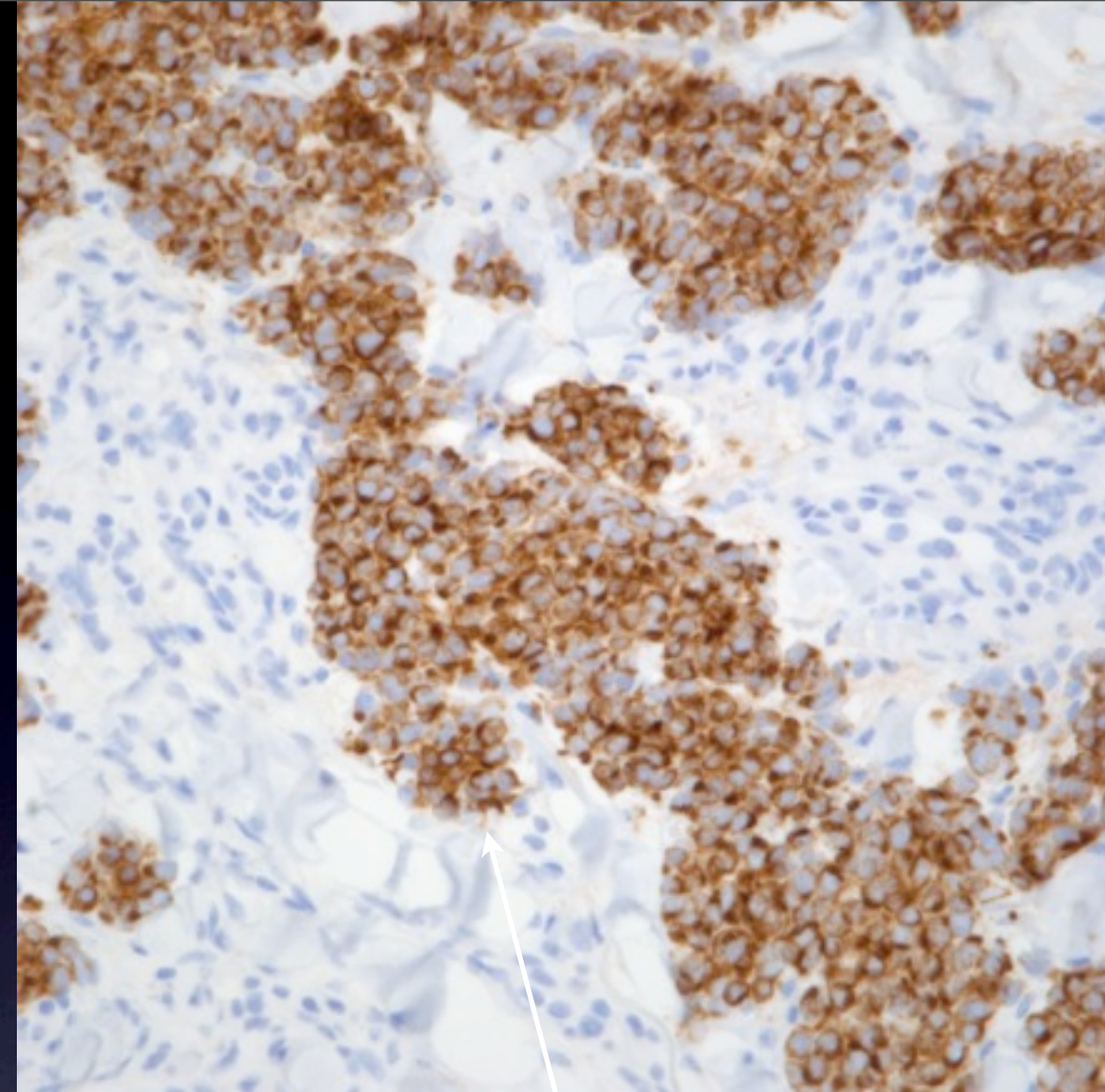


# Merkel Cell Carcinoma





Hyperchromatic cells with  
nuclear molding and  
stippled nuclear chromatin



Paranuclear Dot-like  
positivity  
with Cytokeratin stains